

Takayasu's arteritis affects the vessel walls with an unknown etiology of chronic inflammation. Stenosis, occlusion and aneurysm formations occur in large vessels. Stenotic or occlusive findings are seen predominantly and fusiform/saccular aneurysms are relatively rare (4,9% to 31,9%). Ascending aorta is the most common site of aneurysms. Extracranial carotid artery aneurysm secondary to Takayasu's arteritis is highly rare (1,8% to 3,9%). Treatment is essential to prevent the risk of rupture in such giant aneurysms. Also extracranial carotid artery aneurysms are under risk of cerebral ischemia due to rupture. A 25-year-old female patient was admitted to our hospital with complaints of fever, nausea and carotidynia (one-sided tenderness of the carotid artery). Laboratory tests indicate higher values of sedimentation rate and CRP, respectively 89 mm/h and 57 mg/L. Computed tomographic angiography (CTA) and digital subtraction angiography (DSA) revealed multipl aneurysms in ascending aorta, bilateral common carotid arteries and thoracoabdominal aorta. With clinical, laboratory and imaging findings; the patient was accepted as Takayasu's arteritis in active phase. After for about one year follow-up period, surgical treatment was considered because of reaching surgical limit for ascending aortic aneurysm. Ascending aorta and bilateral common carotid artery aneurysms excised and graft interposed to the ascending aorta and both distal common carotid arteries during selective antegrade perfusion. Postoperative CTA revealed the success of the treatment. Patient discharged at postoperative sixth day without any hemodynamical problem or neurological deficit. Histopathological examination showed chronic inflamatuary disease due to vasculitis and multinuclear giant cells which is patognomonic finding for Takayasu's arteritis. (Figure 1, 2 and 3)

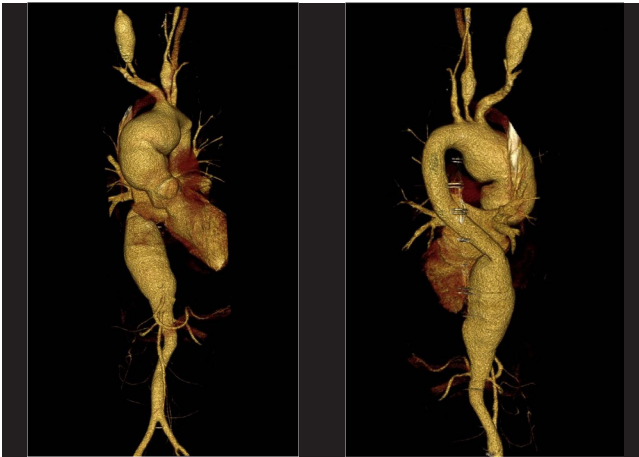


Figure 1. Preoperative 3D reconstructed CTA demonstrated aneurysms in ascending aorta, bilateral common carotid arteries and thoracoabdominal aorta(A,B).

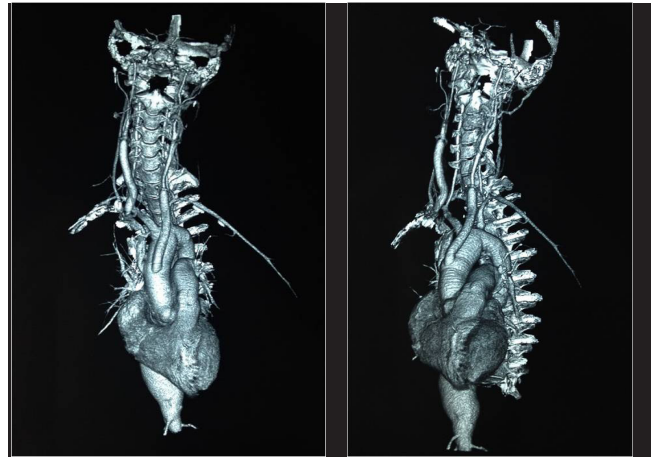


Figure 2. Postoperative 3D reconstructed CTA demonstrated patent grafts in ascending aorta and bilateral common carotid arteries(A,B).

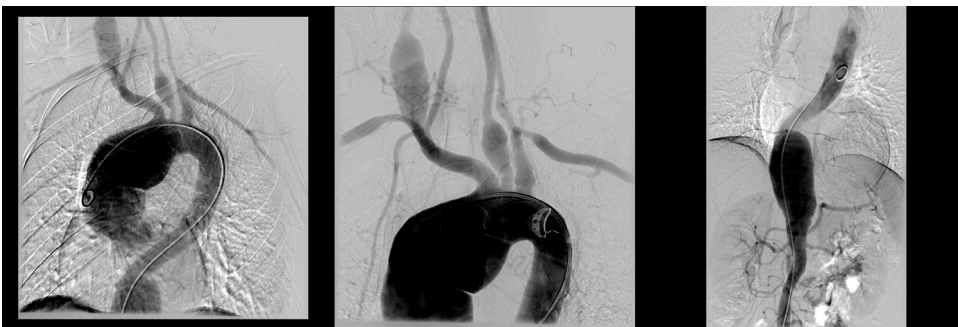

Figure 3. DSA of aortic arch and thoracoabdominal aorta showed aneurysms in ascending aorta, bilateral common carotid arteries and thoracoabdominal aorta (A,B,C).